

# Ocular Perfusion Pressure During Pars Plana Vitrectomy: A Pilot Study

Tommaso Rossi,<sup>1</sup> Giorgio Querzoli,<sup>2</sup> Giampiero Angelini,<sup>3</sup> Alessandro Rossi,<sup>3</sup> Carlo Malvasi,<sup>3</sup> Mario Iossa,<sup>1</sup> and Guido Ripandelli<sup>4</sup>

<sup>1</sup>Eye Hospital of Rome, Rome, Italy

<sup>2</sup>University of Cagliari, DICAAR, Cagliari, Italy

<sup>3</sup>Optikon 2000, Inc., Rome, Italy

<sup>4</sup>Fondazione G.B. Bietti IRCCS, Rome, Italy

Correspondence: Tommaso Rossi, Via Tina Modotti 93, 00142 Rome, Italy; tommaso.rossi@usa.net.

Submitted: April 1, 2014

Accepted: November 5, 2014

Citation: Rossi T, Querzoli G, Angelini G, et al. Ocular perfusion pressure during pars plana vitrectomy: a pilot study. *Invest Ophthalmol Vis Sci*. 2014;55:XXXX-XXXX. DOI:10.1167/iops.14-14493

**PURPOSE.** Unexplained visual field loss after pars plana vitrectomy (PPV) has been reported in up to 14% of all uncomplicated cases with signs varying from visual field defect and disc pallor, to optic atrophy, loss of vision, and phthisis bulbi. Among the postulated pathogenic mechanism is ocular hypoperfusion due to insufficient blood pressure (NBP) and/or elevated IOP, or to their mismatch. The purpose of this study is to assess if, to what extent, and for how long the intraoperative simultaneous variation of IOP and NBP causes mean ocular perfusion pressure (MOPP) to drop below values considered safe, during PPV.

**METHODS.** An IOP sensor placed in the infusion cannula recorded 6 readings per second, while arm systolic and diastolic NBP were taken every 5 minutes throughout surgery and deemed stable in between readings. Supine MOPP was calculated as (115/130) mean arterial pressure - IOP. Surgical monitor video overlay displayed all data in real time and saved them for analysis.

**RESULTS.** Average IOP significantly increased during surgery, while NBP decreased, compared to baseline. As a result, intraoperative MOPP decreased an average 37.1% compared to baseline (range, 13.8%-58.6%;  $P < 0.05$ ). Of 18 patients, 16 (88.8%) had a significant intraoperative MOPP decrease; 15/18 (83.3%) spent more than 20%, and 5/18 (27.7%) more than 50% of the entire surgery below 30 mm Hg MOPP. Surgical maneuvers, such as phacoemulsification, silicone oil removal, and fluid injection, were associated with significant MOPP decrease, while peeling and vitrectomy were not.

**CONCLUSIONS.** The MOPP may decrease significantly in course of PPV, acutely and for longer time. Surgical maneuvers, including silicone oil removal and combined phacoemulsification, pose a higher risk for MOPP reduction. Discretion should be exercised while administering deep sedation, since it may further lower MOPP through undue blood pressure reduction.

**Keywords:** intraocular pressure, mean ocular perfusion pressure, mean arterial pressure, pars plana vitrectomy

Unexplained vision loss after pars plana vitrectomy (PPV) procedures<sup>1</sup> is a condition of unknown origin and protean presentation, varying from silent peripheral field defects to optic disc swelling, afferent pupillary defect, hypotony, loss of vision, and, occasionally, phthisis bulbi.<sup>2</sup> Although the complete presentation is relatively rare, up to 14% of all patients undergoing uneventful PPV may suffer from visual field defects,<sup>3</sup> often associated with disc pallor, making it one of the most prevalent complications.

Postulated pathogenic mechanisms span preoperative underlying conditions and surgical noxae, including potassium ion buffering alterations after silicone oil (SiO) removal,<sup>1</sup> thermal stress, and ischemic changes. Nonarteritic ischemic optic neuropathy (NAION) also has been scrutinized, having been described after cataract,<sup>4</sup> strabismus,<sup>5</sup> PPV,<sup>6</sup> and glaucoma surgery, as well as pre-existing systemic and ocular conditions leading to hypoperfusion: sleep apnea syndrome,<sup>7-9</sup> shock,

anemia,<sup>10</sup> Raynaud phenomenon,<sup>12</sup> atherosclerosis,<sup>13</sup> chronic glaucoma,<sup>14,15</sup> and retrobulbar anaesthesia.<sup>16</sup>

Most of the hypothesized causes share an ocular hypoperfusion mechanism, secondary to blood pressure drop or IOP increase, or a combination of the two.<sup>11</sup>

The purpose of present study is to report on the intraoperative mean ocular perfusion pressure (MOPP) calculated in the course of PPV. Continuous blood and IOP monitoring, has been set up to assess if, to what extent, and how long MOPP drops below safe values during vitreoretinal surgery and speculate on its theoretical pathogenic value.

## MATERIALS AND METHODS

### Sample Population

We included in the study 18 consecutive patients undergoing a standard 23-gauge 3-port PPV (R-Evolution CR; Optikon

TABLE 1. Demographics of Sample Population

Pt #	Age, y	Sex	Diagnosis	Intervention	Duration, m
1	69	M	Cat, pucker	Phaco, IOL, PPV A/F exchange	35
2	67	F	Cat, pucker	Phaco, IOL, PPV, A/F exchange	32
3	45	M	Rd	PPV, A/F exchange, SF6	39
4	70	F	Cat, pucker	Phaco, IOL, PPV, A/F exchange	38
5	34	M	Sio in VC	SiO removal, A/F exchange	28
6	77	F	Endophthalmitis	PPV, A/F exchange, SiO injection	33
7	58	F	RD, luxated IOL	PPV, SiO, IOL removal	36
8	75	M	Cat, pucker	Phaco, IOL, PPV, A/F exchange	47
9	72	M	ERM post PPV	PPV, ERM peel, A/F exchange	28
10	61	F	Cat, pucker	Phaco IOL, PPV, peel, A/F exchange	27
11	71	F	Cat, mh	Phaco IOL, PPV, peel, A/F exchange	31
12	69	M	Cat, pucker	Phaco IOL, PPV, A/F exchange	36
13	78	M	Dislocated lens fragments	PPV IOL sulcus	29
14	48	F	Rd	PPV, A/F exchange, SF6	38
15	66	F	Cat, pucker	phaco, IOL, PPV, A/F exchange, SF6	41
16	32	M	Rd, grt	PPV, A/F exchange, SiO	47
17	76	F	Sio in VC	Sio Removal, A/F exchange	29
18	65	F	Cat, MH	phaco, IOL, PPV, A/F exchange, SF6	40

Patient number, age, sex, diagnosis, surgical steps, and overall length of surgery of sample population. cat, cataract; RD, retinal detachment; VC, vitreous chamber; GRT, giant retina tear; Mh = macular hole.

2000, Inc., Rome, Italy) for a variety of different diagnoses. Demographics, diagnosis, treatment, duration of surgery, and performed surgical maneuvers are reported in Table 1. All patients have been operated by a single surgeon (TR) and were informed about the purpose of the study, which also received IRB approval. All patients received peri- and retrobulbar block with 6 + 2 mL of 10 mg/mL ropivacaine (Naropin; Sanofi-Aventis, Bridgewater, NJ, USA). Monitored anesthesia care with intravenous deep sedation was performed as needed.

All procedures have been video-recorded to be able to match, for every point in time, the surgical maneuver with MOPP, IOP, and blood pressure.

### Noninvasive Blood Pressure Measure (NBP)

Patients received standard continuous monitoring, including venous access, electrocardiography (ECG), oximetry, and NBP monitoring set at 5-minute intervals with brachial cuff (Drager Apollo Anesthesia Workstation; Drager, Inc., Pittsburgh, PA, USA). The NBP values have been considered stable in between two consecutive readings (i.e., we assumed that systolic and diastolic blood pressure remained constant for the five minutes spanning two consecutive readings). Baseline preoperative blood pressure has been considered the mean of 3 readings taken a few days before surgery when preoperative blood testing was performed. Systolic and diastolic NBP were saved to an .xls file for analysis.

### Continuous Intraoperative IOP Measure

The IOP was calculated by means of a pressure sensor (MPX2300DT1; Freescale Semiconductor, Austin, TX, USA) positioned along the infusion cannula, 100 mm away from the eye and distal (infusion fluid streamwise) to the 3-ways stopcock connected in the usual fashion to the BSS and air infusion line. Pressure sensor was set to zero (ambient pressure) immediately before starting surgery and measured 6 readings per second. Preoperative reference IOP was considered the mean of 3 minutes of continuous monitoring with the pressure sensor in place, before the administration of

any sedation and before the starting of surgical maneuvers. Pressure data along with all vitrectomy machine parameters, including infusion bottle height, air pump infusion pressure, cutter rate, aspiration, flow rate, used pump (Venturi or peristaltic), and SiO pump pressure, also were saved to an .xls file for analysis.

The infusion bottle was positioned at a standard height of 40 mm Hg unless otherwise needed for surgical purposes (e.g., bleeding and passive SiO removal when pressure was set to 60 mm Hg) and the air infusion pump was set at 40 mm Hg in all cases.

The infusion of SiO, when needed, was performed through the right hand trochar by means of an armed syringe, after complete gas/fluid exchange with air pump on 40 mm Hg, to avoid sudden pressure loss and prevent SiO to get in touch with the pressure sensor.

To reduce surgical invasiveness and meet IRB recommendation, pressure sensor was placed outside the eye, as close as possible (100 mm). Based on Hagen-Poiseuille law, the loss of pressure along the infusion line between the eye and sensor location equals zero when there is no flow (no trochar leakage and eye connected to infusion line) and has been calculated on the base of the same equation for BSS (1 mm Hg circa) and air (0.2 mm Hg circa) accordingly. All reported measures have been corrected for the loss of pressure calculated and validated by an in vitro model where 2 different sensors have been placed one within the eye and the other at 100 mm along the same infusion tubing as during surgery.

**MOPP Calculation** The MOPP calculation based on supine mean arterial (brachial) pressure (MAP), Mean ophthalmic artery pressure and IOP using the following formulas:<sup>17-20</sup>

$$\text{MAP} = 2/3\text{DNBP} + 1/3\text{SNBP}$$

where DNBP is the diastolic noninvasive (brachial) blood pressure, and SNBP is the systolic noninvasive (brachial) blood pressure.

Mean ophthalmic artery pressure (MOAP) in supine positioning:<sup>21,22</sup>

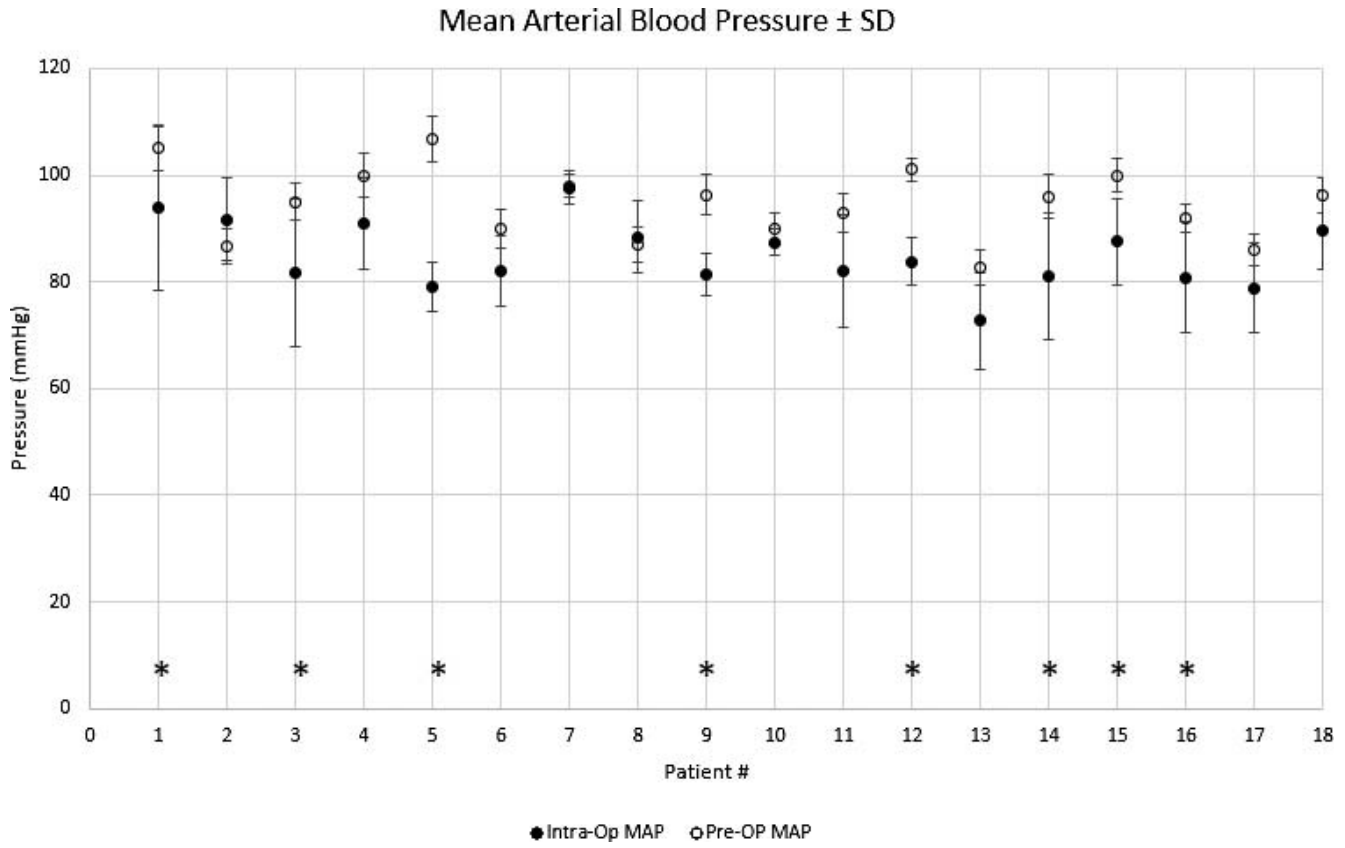


FIGURE 1. Pre- and intraoperative MAP ± SD graph for each patient. \*Patients whose pre- and intraoperative MAP values show significant difference (ANOVA;  $P < 0.05$ ).

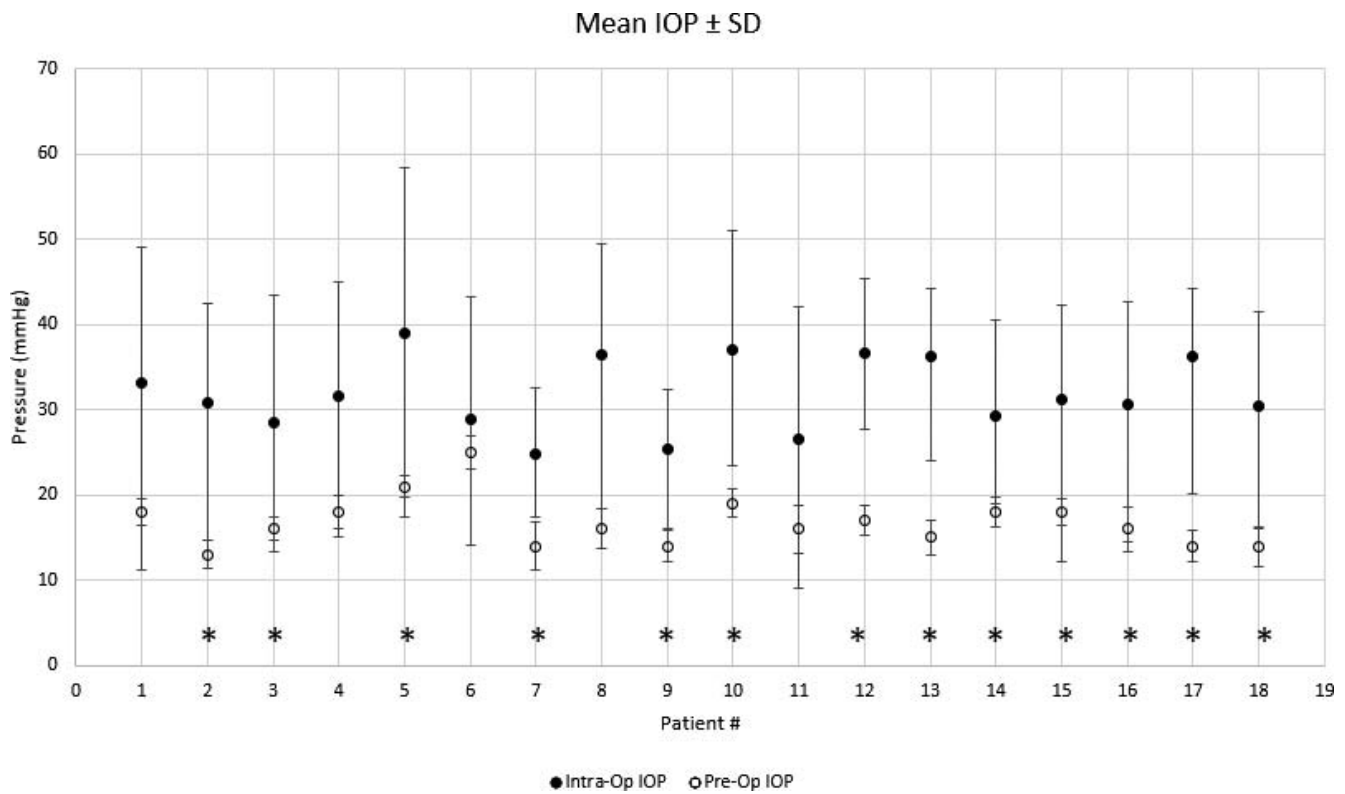


FIGURE 2. Pre- and intraoperative IOP ± SD graph for each patient. \*Patients whose pre- and intraoperative MAP values show significant difference (ANOVA;  $P < 0.05$ ).

Mean Ocular Perfusion Pressure ± SD

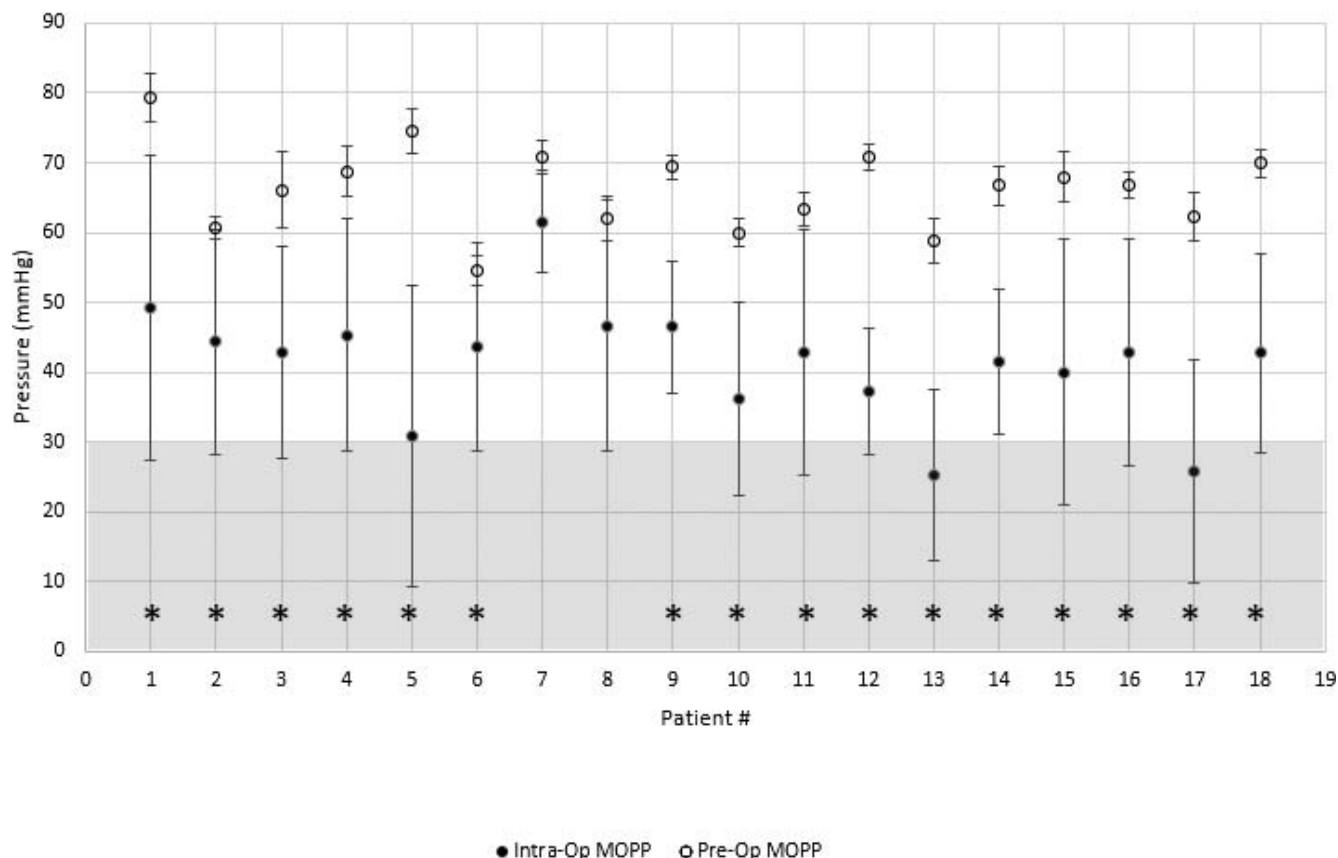


FIGURE 3. Pre- and intraoperative MOPP ± SD graph for each patient. \*Patients whose pre- and intraoperative MAP values show significant difference (ANOVA;  $P < 0.05$ ). The grey area mark MOPP values less than 30 mm Hg, considered dangerous for intraocular structures perfusion.

$$MOAP = (115/130)MAP$$

Mean Ophthalmic Perfusion Pressure (MOPP):

$$MOPP = MOAP - IOP$$

Statistical Analysis

Calculated MOPP, MAP, and measured IOP and NBP data were compared by means of single factor ANOVA. Bonferroni post hoc tests have been implied when comparing simultaneously three or more samples (i.e., different phases of the same surgery). Significance ( $P$ ) has been set at 0.05 level in all cases except when the Bonferroni procedure was involved, in which cases  $\alpha$  0.05 was divided for the overall number of tests (e.g.,  $\alpha = 0.05/3 = 0.0167$ ).

RESULTS

Pre- and intraoperative MAP is reported in Figure. 1. Of 18 patients, 8 (44.4%) showed a significant MAP decrease during the course of surgery, most likely due to sedation.

Mean pre- and intraoperative IOP readings are reported in Figure 2; 14/18 patients (77.8%) had a significant IOP increase during the surgical procedure.

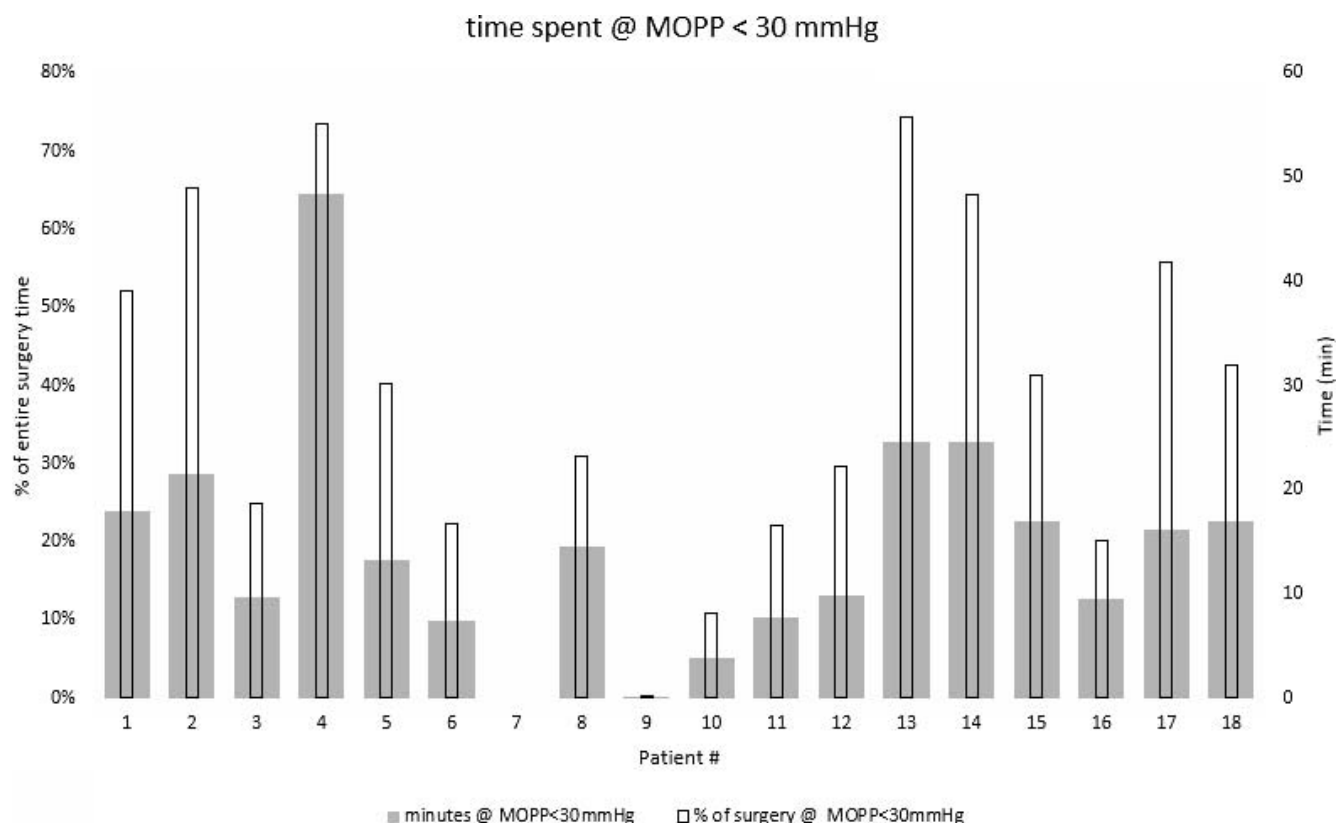
Pre- and intraoperative MOPP is shown in Figure 3 where the area below 30 mm Hg considered at higher risk for

dangerously low perfusion of ocular structures<sup>21</sup> is shadowed. Of 18 patients, 16 (88.8%) had a significant intraoperative MOPP decrease, compared to baseline and 17/18 patients (94.4%) dipped at least once, during surgery, below 30 mm Hg MOPP. The mean perfusion pressure throughout surgery was below the physiologic range of 50 to 60 mm Hg<sup>23,24</sup> in 5/18 (27.7%) and the inferior boundary of the mean MOPP ± SD dropped below 30 mm Hg in all patients except #7 (Fig. 3).

The time each patient spent at MOPP less than 30 mm Hg, considered overtly dangerous, and the corresponding percentage of the entire surgical time is displayed in Figure 4. A total of 15 patients (15/18 = 83.3%) spent more than 20% and 5/18 (27.7%) more than 50% of the entire surgery below 30 mm Hg of MOPP. Mean intraoperative MOPP decrease compared to baseline was 37.1% (range, 13.8%-58.6%).

Selected Case Reports

We herein report in details MOPP, IOP, and blood pressure data of patients during specific surgical maneuvers that encompass most of the vitreoretinal surgery armamentarium (see Table 1 for the demographics). Table 2 reports the average MOPP per surgical step of each selected case demonstrating that each selected patient experienced significant MOPP changes during the different maneuvers of the same procedure ( $P < 0.001$  for all patients).



**FIGURE 4.** Time spent during surgery at MOPP less than 30 mm Hg. Note that all but patient #7 spent some time below 30 mm Hg and 15/18 at least 20% of the entire procedure. A *double vertical (y)* axis is displayed: *left vertical axis* (primary *y* axis) reports the percent of entire surgery and *right y* axis (secondary *y* axis) reports time in minutes.

**Patient # 5: SiO Removal Status Post PPV for Retinal Detachment (Fig. 5).** The procedure starts with passive SiO-balanced salt solution (SiO-BSS) exchange obtained by increasing infusion bottle height to 60 mm Hg. The IOP raises to almost 60 mm Hg as if the ports were obstructed, due to high SiO viscosity. Consequently MOPP decreases to dangerous levels despite normal blood pressure. As soon as SiO finishes, approximately minute 11, IOP goes down because the ports are no longer obstructed by SiO and the bottle height can be lowered back to 35 mm Hg; MOPP raises abruptly although blood pressure does not change. The third step is a double air/fluid exchange (A/F exchange) for thorough emulsion removal; the IOP under air infusion (40 mm Hg pressure) is much more unstable due to loss through open ports as the instruments are removed and MOPP changes consequently although remaining within acceptable values.

**Patient #6: PPV + Epiretinal Membrane (ERM) Peel + SiO Tamponade for Endophthalmitis (Fig. 6).** The initial 7 minutes are devoted to anterior chamber (AC) lavage and fibrinous membrane removal, to gain vision of the vitreous chamber. The IOP is unstable due to AC depth fluctuations and spikes up when viscoelastic fluid is injected at 3 minutes time.

Blood pressure is initially higher as the patient is very nervous and MOPP behaves consequently. During PPV and membranes peeling the IOP remains mostly stable with a few dips due to excessive cutter suction. During A/F exchange IOP lowers and MOPP raises consequently. No significant change in IOP and MOPP is detected throughout SiO injection, towards the end of the procedure.

**Patient #10: Phacoemulsification (Phaco) + IOL + PPV + ERM peel + A/F Exchange for Macular Pucker + Cataract (Fig. 7).** The initial 5 minutes span the phacoemulsification with initial lower IOP and significant spikes related to viscoelastic fluid injection and IOL insertion manoeuvres. The MOPP lowers during PPV and peeling due to infusion bottle height. Note than IOP is higher during peeling than during vitrectomy, due to cutter aspiration. The final A/F exchange, as in the previous cases, shows IOP changes related to trocar opening and obstruction by the instruments and low air viscosity.

**DISCUSSION**

The MOPP is the differential between arterial pressure and IOP, and guarantees nourishment to all intraocular structures. Long-

**TABLE 2.** MOPP Values During Different Surgical Maneuvers of the 3 Selected Case Reports.

Patient #	MOPP During Surgical Steps						P
	Phaco+ IOL	PPV	Peel	SiO Inj/Ext	AC/VC Lavage	A/F Ex	
5	-	-	-	8.19 ± 4.88	45.25 ± 11.37	53.59 ± 11.71	<0.0001
6	-	38.58 ± 16.81	40.13 ± 2.64	45.15 ± 10.3	53.51 ± 9.34	52.68 ± 13.23	<0.0001
10	40.70 ± 4.29	27.45 ± 4.58	35.17 ± 2.21	-	-	50.74 ± 9.89	<0.0001

Note that perfusion significantly changes during the different steps of the same procedure.

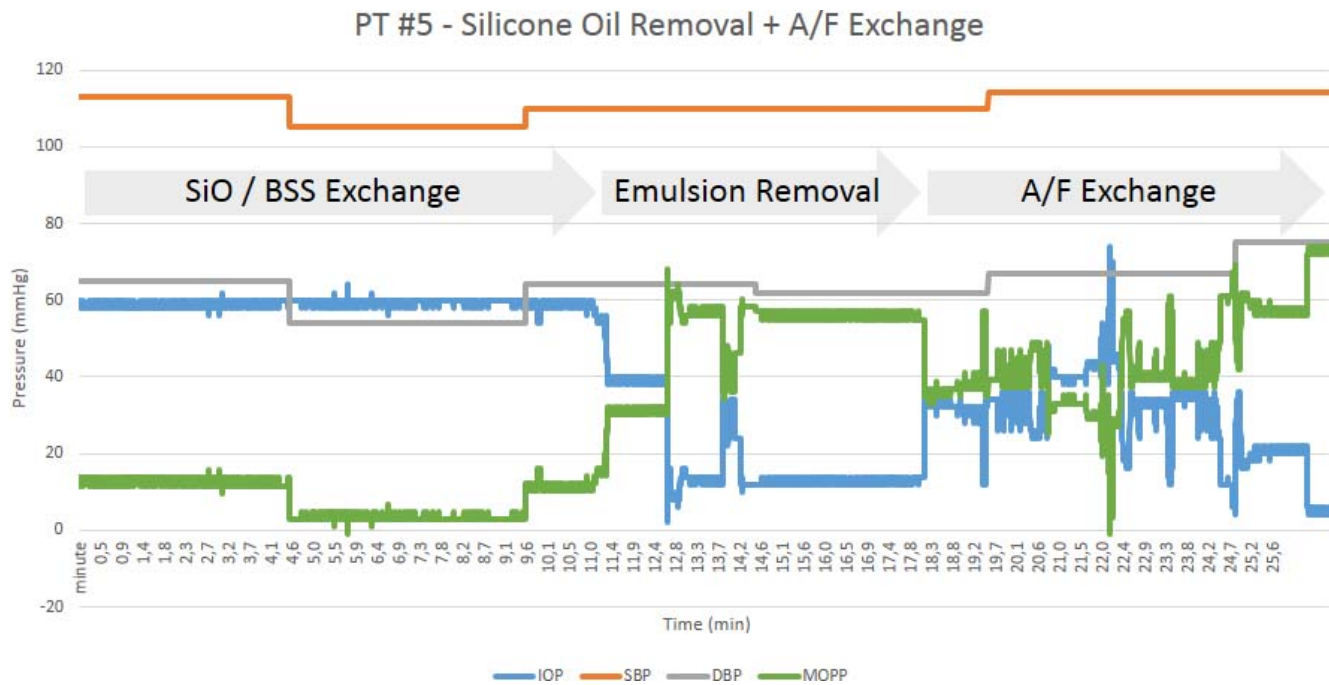


FIGURE 5. Patient #5 continuous recording of IOP, systolic blood pressure (SBP), diastolic blood pressure (DBP), and MOPP. Note MOPP fluctuation during the different steps of surgery.

standing deficient MOPP may cause irreversible damage to the optic nerve due to its limited autoregulation<sup>25</sup> capability, while acute IOP elevation can block retrograde transport of neurotrophic factors.

In course of PPV, IOP often is increased for a number of different reason, including mechanical stress imposed by surgical maneuvers, viscous or perfluorocarbon fluid injection, deliberate increase of infusion bottle height to limit bleeding. On the other hand, the systemic pressure can drop significantly due to deep patient sedation and supine positioning. The net result is a potentially dangerous decrease of the ocular perfusion pressure.

Intraoperative MOPP reduction, therefore, retains a 2-fold origin: arterial pressure drop and IOP increase. Both factors coexisted in our patients, showing MAP reduction due to

sedation (Fig. 1), and raised IOP (Fig. 2) throughout surgery. As a result, MOPP dropped significantly (Fig. 3), often remaining below the critical limit of 30 mm Hg for as much as 50% of the entire surgery (Fig. 4).

Normal MOPP range for young healthy subjects is between 45 and 55 mm Hg<sup>26</sup> with a physiologic nocturnal dip of 10% to 20%.<sup>27</sup> Although it is difficult to ascertain overtly dangerous MOPP values, it is clear that our patients experienced a significant MOPP decrease from their own baseline level (Fig. 3) and 37.1% average intraoperative dip, which is consistently higher than deemed sufficient for visual field damage by glaucoma specialists.<sup>22</sup>

Not only how much, but also how long ischemia can be tolerated by ocular structures is uncertain: Hayreh<sup>28</sup> found limited photoreceptor damage after 90 minutes of central

Investigative Ophthalmology & Visual Science

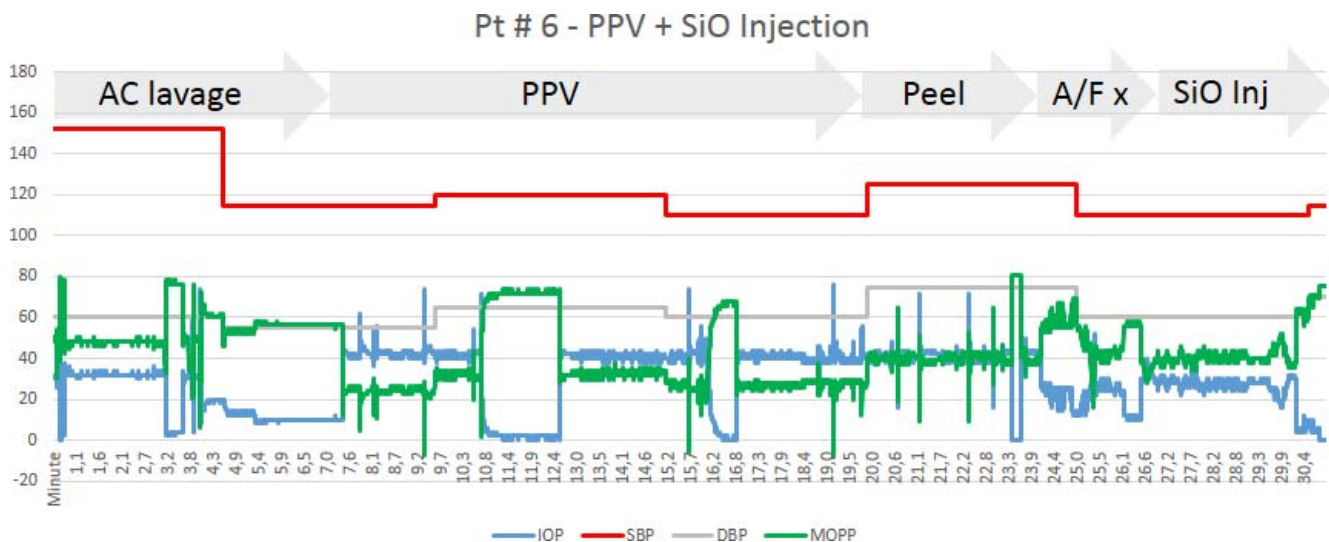


FIGURE 6. Patient #6 continuous recording of IOP, SBP, DBP, and MOPP.

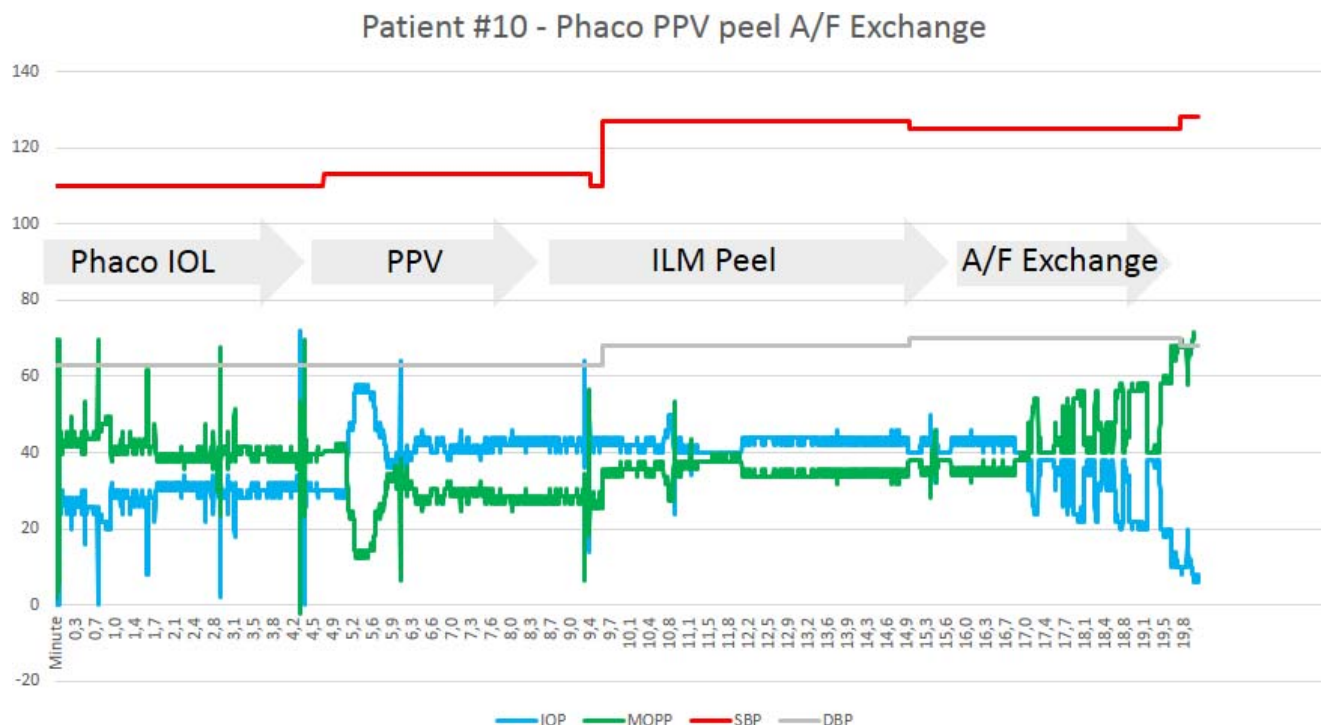


FIGURE 7. Patient #10 continuous recording of IOP, SBP, DBP, and MOPP.

retinal artery occlusion, but ganglion cells seem to be a lot more sensitive, showing mitochondrial disruption after 45 minutes.<sup>29</sup> Considering that most PPVs may last more than that, it is conceivable that intraoperative MOPP reduction can result in ischemic changes, especially in predisposed patients.<sup>6</sup>

Patients' comorbidity could also contribute to intraoperative cellular damage: aging, high myopia, diabetes, atherosclerosis, carotid stenosis,<sup>30</sup> and retinal detachment, all impair significantly optic nerve head perfusion regulatory mechanisms.<sup>25</sup> Moreover, surgical trauma, photic stress, low infusion fluid temperature, and extensive laser treatment increase metabolic demand, worsening hypoperfusion consequences.

Whenever good analgesia was achieved, intraoperative blood pressure showed modest correlation to surgical manoeuvres: NBP tended to be initially higher, possibly due to anxiety and lowered thereafter, as sedation ensued. Deeper sedation, occasionally required, resulted in MOPP decrease (Fig. 6, minute 5) while occasional pain determined temporary NBP rise and consequent MOPP increase (Fig. 7, minute 10). However, increasing blood pressure to improve MOPP is not a viable option (even if perfusion is directly proportional to NBP), since high blood pressure causes significant central and peripheral vasoconstriction, and causes systemic morbidity. As a result, the only feasible way to maintain an appropriate MOPP throughout surgery is to maintain IOP within a strict range while avoiding NBP dips (Fig. 8).

Several investigators measured intraoperative IOP during cataract surgery,<sup>31</sup> scleral buckling<sup>32</sup> and PPV,<sup>33-35</sup> and some retrospectively correlated it with blood pressure, to derive MOPP.<sup>6</sup> We synchronized blood pressure and IOP measures with video recording, to establish a "point to point" correlation between instantaneous MOPP and surgical maneuver.

The reported selection of cases (Figs. 5-7) show different elevated IOP patterns: sustained IOP increase and sporadic spikes. Sustained elevations approximately 40-50 mm Hg that last minutes generally are due to deliberate infusion bottle heightening, for hemostasis (Fig. 7, minutes 5-6), SiO removal

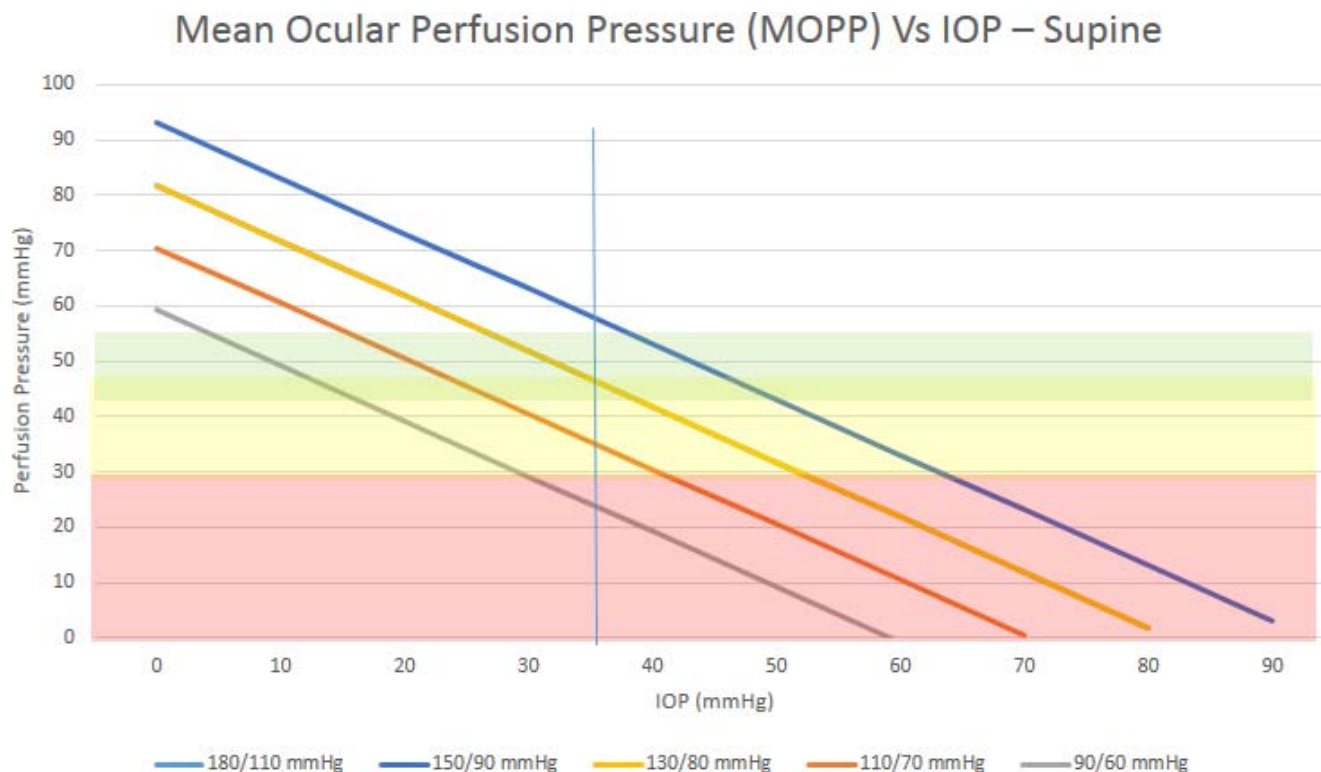
(Fig. 5, minutes 1-12) or for other purposes. Sporadic spikes, instead, may exceed 70 mm Hg for a few seconds and mostly result from eye manipulation, grasping, rotating, and/or sudden injection of small amount of liquids, such as viscous fluids, perfluorocarbon, or dyes within the vitreous or anterior chamber. Both occurrences can be dangerous: acute IOP elevations decrease juxtacapsular and optic nerve-head blood flow of 7% to 8% per 10-mm Hg IOP increase<sup>36</sup> and sudden or sustained IOP elevation during PPV can cause ganglion cell structural<sup>37</sup> and functional abnormality.<sup>38</sup>

Passive SiO/fluid exchange determined the longer lasting MOPP decrease while phacoemulsification caused IOP sudden spikes, due to viscous fluid injection and frequent bulb manipulation. Vitrectomy (Fig. 6, minutes 12-20) and peeling (Fig. 7, minutes 10-15) were mostly performed under a steady pressure state (after a brief transition), where cutter suction and/or trocar leaks are promptly replaced by fluid infusion. The A/F exchanges (Figs. 5-7, final minutes), on the contrary, showed wide MOPP variation entirely due to IOP changes, secondary to trocar opening and obstruction by the flute needle.

The MOPP also varied significantly during different steps of the same surgery, suggesting that virtually all procedures pose the patient at risk for being exposed to dangerously low perfusion for some time.

Pitfalls of the present study are numerous, and include the limited and single-surgeon series of patients, the assumption of an invariant blood pressure in between consecutive readings and positioning the IOP sensor close, but not within the eye. We believe the study outcome was not significantly impaired due to such biases.

In conclusion, we found a consistent and prolonged reduction of intraoperative MOPP during PPV and particularly during certain surgical steps. Local anesthesia with sedation and IOP rise for surgical purposes can further decrease perfusion, and suggest an explanation for sporadic optic nerve damage after uneventful vitrectomy. Further study on the issue and better and ideally synchronous intraoperative control of



**FIGURE 8.** Nomogram of supine MOPP versus IOP as a function of SBP and DBP values. Note that at IOP of 35 mm Hg, deemed safe throughout most PPV procedures, patient with lower blood pressure ranges show frankly critical MOPP values. At 40 mm Hg IOP all exemplified blood pressure ranges should be considered borderline for insufficient perfusion with the only exception of frankly dangerous systolic and diastolic values. The nomogram clearly shows that although low blood pressure can bring the patients' MOPP towards the dangerous area, simply increasing blood pressure is not a viable option.

IOP and blood pressure will help deliver a better care and safer surgery, minimizing ischemic complications.

### Acknowledgments

The authors alone are responsible for the content and writing of the paper.

Disclosure: **T. Rossi**, None; **G. Querzoli**, None; **G. Angelini**, Optikon 2000, Inc. (E); **A. Rossi**, Optikon 2000, Inc. (E); **C. Malvasi**, Optikon 2000, Inc. (E); **M. Iossa**, None; **G. Ripandelli**, None

### References

- Cazabon S, Groenewald C, Pearce IA, Wong, D. Visual loss following removal of intraocular silicone oil. *Br J Ophthalmol*. 2005;89:799-802.
- Hayreh SS. Posterior ischaemic optic neuropathy: clinical features, pathogenesis, and management. *Eye (Lond)*. 2004;18:1188-1206.
- Taban M, Lewis H, Lee MS. Nonarteritic anterior ischemic optic neuropathy and 'visual field defects' following vitrectomy: could they be related? *Graefes Arch Clin Exp Ophthalmol*. 2007;45:600-605.
- McCulley TJ, Lam BL, Feuer WJ. Incidence of nonarteritic anterior ischemic optic neuropathy associated with cataract extraction. *Ophthalmology*. 2001;108:1275-1278.
- Tsagakaki M, Rowlands A. Visual loss due to non-arteritic anterior ischemic optic neuropathy (NAION) immediately following routine strabismus surgery under general anesthesia—a case report. *Strabismus*. 2012;20:121-123.
- Bansal AS, Hsu J, Garg SJ, et al. Optic neuropathy after vitrectomy for retinal detachment: clinical features and analysis of risk factors. *Ophthalmology*. 2012;119:2364-2370.
- Gaillard MC, Zambaz BD, Borruat FX. Posterior ischemic optic neuropathy: case report of a rare complication after general surgery. *Klin Monbl Augenbeilkd*. 2004;221:421-423.
- Pandey KH, Chandrakar AK, Garg ML. Perioperative visual loss with non-ocular surgery: Case report and review of literature. *Indian J Ophthalmol*. 2013;62:503-505.
- Abdal H, Pizzimenti JJ, Purvis CC. The eye in sleep apnea syndrome. *Sleep Med*. 2006;7:107-115.
- Foroozan R, Buono LM, Savino PJ. Optic disc structure and shock-induced anterior ischemic optic neuropathy. *Ophthalmology*. 2003;110:327-331.
- Hayreh SS. Ischemic optic neuropathies, where are we now? *Graefes Arch Clin Exp Ophthalmol*. 2013;251:1873-1884.
- Chu ER, Lee AW, Chen CS. Resolution of visual field constriction with verapamil in a patient with bilateral optic neuropathy, migraine and Raynaud's phenomenon. *Intern Med J*. 2009;39:851-853.
- Arda H, Birer S, Aksu M, et al. Obstructive sleep apnoea prevalence in non-arteritic anterior ischaemic optic neuropathy. *Br J Ophthalmol*. 2013;97:206-209.
- Bonomi L, Marchini G, Marraffa M, et al. Vascular risk factors for primary open angle glaucoma: the Egna-Neumarkt Study. *Ophthalmology*. 2000;107:1287-1293.
- Kuriyan AE, Lam BL. Non-arteritic anterior ischemic optic neuropathy secondary to acute primary-angle closure. *Clin Ophthalmol*. 2013;7:1233-1238.
- Devoto MH, Kersten RC, Zalta AH, Kulwin DR. Optic nerve injury after retrobulbar anesthesia. *Arch Ophthalmol*. 1997;115:687-688.



17. Caprioli J, Coleman AL. Blood flow in glaucoma discussion. Blood pressure, perfusion pressure, and glaucoma. *Am J Ophthalmol*. 2010;149:704-712.
18. Bill A. Physiological aspects of the circulation in the optic nerve. In: Heilmann K, Richardson KT, eds. *Glaucoma: Conceptions of a Disease*. Philadelphia, PA: WB Saunders; 1978:97-103.
19. Choi J, Jeong J, Cho H-S, Kook MS. Effect of nocturnal blood pressure reduction on circadian fluctuation of mean ocular perfusion pressure: a risk factor for normal tension glaucoma. *Invest Ophthalmol Vis Sci*. 2011;47:831-836.
20. Hayreh SS. Blood flow in the optic nerve head and factors that may influence it. *Prog Retin Eye Res*. 2001;20:595-624.
21. Liu JHK, Gokhale PA, Loving RT, et al. Laboratory assessment of diurnal and nocturnal ocular perfusion pressures in humans. *J Ocul Pharmacol Ther*. 2003;19:291-297.
22. Quaranta L, Katsanos A, Russo A, Riva I. 24-hour intraocular pressure and ocular perfusion pressure in glaucoma. *Surv Ophthalmol*. 2013;58:26-41.
23. Liu JH, Gokhale PA, Loving RT, Kripke DE, Weinreb RN. Laboratory assessment of diurnal and nocturnal ocular perfusion pressures in humans. *J Ocul Pharmacol Ther*. 2003;19:291-297.
24. Sehi M, Flanagan JG, Zeng L, Cook RJ, Trope GE. Anterior optic nerve capillary blood flow response to diurnal variation of mean ocular perfusion pressure in early untreated primary open-angle glaucoma. *Invest Ophthalmol Vis Sci*. 2005;46:4581-4587.
25. Riva CE, Hero M, Titze P, Petrig B. Autoregulation of human optic nerve head blood flow in response to acute changes in ocular perfusion pressure. *Graefes Arch Clin Exp Ophthalmol*. 1997;35:618-626.
26. Kim M, Kim SS, Kwon HJ, Koh HJ, Lee SC. Association between choroidal thickness and ocular perfusion pressure in young, healthy subjects: enhanced depth imaging optical coherence tomography study. *Invest Ophthalmol Vis Sci*. 2012;53:7710-7717.
27. Millar-Craig MW, Bishop CN, Raftery EB. Circadian variation of blood pressure. *Lancet*. 1978;1:795-797.
28. Hayreh SS. Acute retinal arterial occlusive disorders. *Prog Retin Eye Res*. 2011;30:359-394.
29. Adachi M, Takahashi K, Nishikawa M, Miki H, Uyama M. High intraocular pressure-induced ischemia and reperfusion injury in the optic nerve and retina in rats. *Graefes Arch Clin Exp Ophthalmol*. 1996;234:445-451.
30. Strauss AL, Rieger H, Roth FJ, Schoop W. Doppler ophthalmic blood pressure measurement in the hemodynamic evaluation of occlusive carotid artery disease. *Stroke*. 1989;20:1012-1015.
31. Armeniades CD, Moorhead LC. Hydrodynamic analysis of intraocular pressure changes during anterior chamber procedures. *J Cataract Refract Surg*. 1992;18:444-448.
32. Gardner TW, Quillen DA, Blankenship GW, Marshall WK. Intraocular pressure fluctuations during scleral buckling surgery. *Ophthalmology*. 1993;100:1050-1054.
33. Parel JM, Parrish RK 2nd, Nose I. An intraoperative intraocular pressure monitor. *Ophthalmic Surg*. 1987;18:371-374.
34. Blumenthal M, Cahane M, Ashkenazi I. Direct intraoperative continuous monitoring of intraocular pressure. *Ophthalmic Surg*. 1992;23:132-134.
35. Moorhead LC, Gardner TW, Lambert HM, et al. Dynamic intraocular pressure measurements during vitrectomy. *Arch Ophthalmol*. 2005;123:1514-1523.
36. Michelson G, Groh MJ, Langhans M. Perfusion of the juxtapapillary retina and optic nerve head in acute ocular hypertension. *Ger J Ophthalmol*. 1996;5:315-321.
37. Uchida A, Shinoda K, Matsumoto CS, et al. Acute visual field defect following vitrectomy determined to originate from optic nerve by electrophysiological tests. *Case Rep Ophthalmol*. 2012;3:396-405.
38. Minami M, Oku H, Okuno T, Fukuhara M, Ikeda T. High infusion pressure in conjunction with vitreous surgery alters the morphology and function of the retina of rabbits. *Acta Ophthalmol Scand*. 2007;85:633-639.

**Queries for iovs-55-12-31**

- 1. Author: This article has been lightly edited for grammar, style and usage. Please compare against your original document and make changes on these pages. Please limit your corrections to substantive changes that affect meaning. If no change is required in response to a question, please writing “OK as set” in the margin. Copy editor**
- 2. Author: Carefully check the spelling and order of the author names and check the affiliations for all of the authors.**
- 3. Author: Make sure that ALL funding/financial support is listed in the information following the Acknowledgments.**
- 4. Author: Please confirm wording of précis: Ocular perfusion pressure during vitrectomy drops significantly due to intraocular pressure increase and arterial pressure lowering. Synchronous control of blood and ocular pressure could avoid prolonged ocular hypoperfusion and possibly prevent postsurgical ischemic optic neuropathy. Copy editor**
- 5. Author: Reference 11 is cited out of order in text. Please renumber references in document and reference list as necessary so that all references are cited in order in text. Copy editor Copy editor**
- 6. Author: Please provide statement of compliance with the Declaration of Helsinki. Copy editor**